

# Acute tubulointerstitial nephritis and polyclonal hypergammaglobulinaemia: Which is the culprit?

Ana E. Sirvent,<sup>1</sup> Ricardo Enríquez,<sup>1</sup> Tania Muci,<sup>2</sup> Francisco Javier Ardoy-Ibañez,<sup>3</sup> Isabel Millán,<sup>1</sup> Amadeo Almiñana,<sup>4</sup> Rosalía Ruiz-Ferrús,<sup>1</sup> Luis Jiménez del Cerro<sup>1</sup>

<sup>1</sup>Nephrology Section; <sup>2</sup>Pathology Section; <sup>3</sup>Diagnostic Radiology Service; <sup>4</sup>Ophthalmology Section, Hospital General Universitario de Elche, Spain

## Abstract

Proton pump inhibitors (PPIs) are among the most frequent implicated drugs in acute tubulointerstitial nephritis (ATIN), nevertheless it is important to report cases with atypical profiles. A 80-year-old female, exposed during 34 months to omeprazole, presented with polyclonal hypergammaglobulinaemia and renal failure. After stopping omeprazole there was a partial improvement in serum creatinine and IgG. Renal biopsy revealed ATIN; immunohistochemistry for IgG4 was negative. Treatment with steroids and mycophenolate sodium improved renal function and normalized immunoglobulins. The lack of data of other entities and the patient's evolution strongly point omeprazole as the culprit. After 27 months of follow-up, she remains clinical and analytically stable. ATIN caused by PPIs may appear after a long period of exposure and may be accompanied by analytical anomalies that simulate a systemic disease.

## Introduction

Acute tubulointerstitial nephritis (ATIN) can be induced by drugs (the most common cause in developed countries), infections, autoimmune diseases, and neoplasms, among other causes.<sup>1</sup> Proton pump inhibitors (PPIs) are some of the drugs most frequently implicated in ATIN.<sup>2,3</sup>

ATIN caused by PPIs is well documented; it is not usually accompanied by systemic manifestations and the period of exposure, although being variable, most often ranges between 10-11 weeks.<sup>1</sup> The recovery of renal function is often incomplete, and progression to chronic interstitial nephropathy can occur.<sup>4</sup> Given the widespread use of these drugs, it is impor-

tant to report cases with less typical profiles.

We describe a patient who developed ATIN and polyclonal hypergammaglobulinaemia after long exposure to omeprazole.

## Case Report

An 80-year-old female was admitted (in October 2015) for renal insufficiency detected in a control analysis; 3 months earlier her serum creatinine was 1.09 mg/dL, eGFR (estimated glomerular filtration rate) using the CKD-EPI formula 47.9 mL/min/1.73 m<sup>2</sup>. Urinalysis before admission was normal (normal sediment and 24-hour proteinuria was negative (<4 mg/dL)). She reported nocturia (2-3 times), asthenia, and anorexia in recent months, no decrease in diuresis or other systemic symptoms.

Personal history: Hypertension, ischaemic heart disease, hiatal hernia, primary autoimmune hypothyroidism, positive ANA with negative anti-DNA antibodies, did not satisfy systemic lupus erythematosus (SLE) criteria.

Usual medications: omeprazole 20 mg/day, acetylsalicylic acid 100 mg/day, levothyroxine 75 µg/day, atorvastatin 80 mg/day, lorazepam 2 mg/day (all for the previous 34 months), irbesartan 150 mg/day (for the previous 7 months), nifedipine gastrointestinal therapeutic system (GITS) 30 mg/day (for the previous 5 months).

Physical examination highlights: Afebrile, blood pressure 138/77 mm Hg; other findings were unremarkable. Diuresis: 2300 ml in the first 24 hours.

Laboratory examination findings: hemoglobin 10.9 g/dL, leukocytes 7460/mm<sup>3</sup> (eosinophils 70/mm<sup>3</sup>), urea 81 mg/dL, creatinine 2.54 mg/dL; coagulation, platelets, liver function tests, electrolytes and other routine biochemical parameters were normal. C-reactive protein 16.8 mg/L (normal value (nv)<3), IgG 2689 mg/dL (nv 680-1530), IgG1 2130 mg/dL (nv 490-1140), IgG2 348 mg/dL (nv 150-640), IgG3 146 mg/dL (nv 20-110), IgG4 65 mg/dL (nv 8-140), IgA 390 mg/dL (nv 70-400), IgM 201 mg/dL (nv 60-260). High-resolution electrophoresis of serum samples showed an increase in polyclonal IgG. ANA 1/1280 (nuclear membrane and cytoplasmic patterns); the following results were normal/negative: C3, C4, rheumatoid factor, Ro/SSA, La/SSB, anti-histone antibodies, anti-DNA antibodies, anti-Sm antibodies, anti-RNP antibodies, anti-Scl-70 antibodies, anti-Jo-1 antibodies and ANCA. Angiotensin-converting enzyme 55 U/l (nv 8-70); TSH 0.40 microUI/mL (nv 0.465-4.68), free T4 1.09 ng/dL (nv 0.71-1.77),

Correspondence: Ana E. Sirvent, Nephrology Section, Hospital General Universitario de Elche, Camí de l'Almàssera 11, 03203 Elche, Spain.  
E-mail: anaesipe@gmail.com

Key words: Acute tubulointerstitial nephritis; Hypergammaglobulinaemia; Omeprazole; Renal failure.

Contributions: AES and RE drafted the manuscript and were the treating physicians; TM performed the evaluation of the renal biopsy; FJAI and AA made significant contributions to the clinical data. RR-F reviewed the patient at follow up. IM and LJC made the literature search. All authors read and approved the final manuscript.

Conflict of interest: the authors declare no potential conflict of interest.

Funding: none.

Received for publication: 29 January 2018.

Revision received: 23 October 2018.

Accepted for publication: 2 November 2018.

This work is licensed under a Creative Commons Attribution NonCommercial 4.0 License (CC BY-NC 4.0).

©Copyright A.E. Sirvent et al., 2018  
Licensee PAGEPress, Italy  
Clinics and Practice 2018; 8:1065  
doi:10.4081/cp.2018.1065

anti-TPO 135.20 IU/mL (nv 1-16). The patient's 24-hour proteinuria was 575 mg (with a tubular pattern in high-resolution electrophoresis). Sediment: 6-12 leukocytes/HPF, negative glucose, fractional excretion of sodium 2.1%. Urine culture was negative. Tuberculosis skin testing and QuantiFERON were negative; serology showed previous exposure to CMV, EBV, and parvovirus B19; and the patient was negative for HBsAg, anti-HBc, anti-HBs, HCV, and HIV as well as anti-*Leishmania* IgG antibodies.

ECG: normal. Abdominal ultrasound: cholelithiasis, normal kidney size (right kidney 105×43 mm, left kidney 120×49 mm). Thyroid ultrasound showed a gland of reduced size. Chest-abdomen-pelvis CT: no pulmonary infiltrates or adenopathies. An ophthalmologic examination revealed no signs of uveitis. The Schirmer test was negative, salivary gland scintigraphy was normal, and labial mucosa biopsy showed salivary glands without lesions.

The possibility of ATIN (caused by a systemic disease or drugs) was considered. Omeprazole, irbesartan, and acetylsalicylic acid were discontinued, atorvastatin was

decreased to 20 mg/day, ranitidine was added, and the patient's other drugs were maintained. Two weeks later, creatinine had decreased to 1.56 mg/dL. A percutaneous renal biopsy (27 glomeruli, 11 sclerosed) revealed a dense interstitial infiltrate with lymphocytes, plasma cells, and occasional eosinophils, tubulitis and interstitial oedema; interstitial fibrosis in less than 25% of the sample; non-sclerosed glomeruli were normal, few of them showed slight mesangial matrix expansion presumably age related (Figure 1). Granulomas were not seen. Immunofluorescence study was negative. Immunohistochemistry revealed less than 10 IgG4-positive plasma cells/HPF, and the IgG4/IgG plasma cell ratio was approximately 10%.

Three weeks after the patient's admission, her IgG had declined to 1878 mg/dL. Serum creatinine did not improve, so we decided to administer additional treatment. Because the patient was reluctant to receive high doses of corticosteroids, prednisone (40 mg/day for 4 days, 30 mg/day for 1 week, and decreasing doses thereafter until its suppression in 10 weeks) and mycophenolate sodium (360 mg/8 hours for 8 weeks and 360 mg/12 hours for 8 weeks) were administered. The patient's creatinine improved, and her IgG normalized. Acetylsalicylic acid and irbesartan were reintroduced in November 2015, and atorvastatin was increased to 40 mg/day in December 2015 (Figure 2).

Two additional ophthalmologic examinations (at 9 and 19 months after diagnosis) disclosed no signs of uveitis. During 27 months of follow-up, no new clinical manifestations appeared; a chest-abdomen-pelvis CT scan showed no relevant changes; angiotensin-converting enzyme, IgG and IgG4 were normal; Ro/SSA and La/SSB were negative; ANA was 1/320 and creatinine was around 0.97- 1.08 mg/dL (eGFR CKD-EPI 54.4-47.7 mL/min/1.73 m<sup>2</sup>).

## Discussion

Our diagnostic impression was ATIN, and the evidence of polyclonal hypergammaglobulinaemia led us to consider infections, Sjögren syndrome, sarcoidosis, SLE, IgG4-related ATIN, and tubulointerstitial nephritis and uveitis (TINU) syndrome. These entities were excluded by a lack of data and the evolution of the patient's condition, although we offer certain comments regarding the final 2 possibilities.

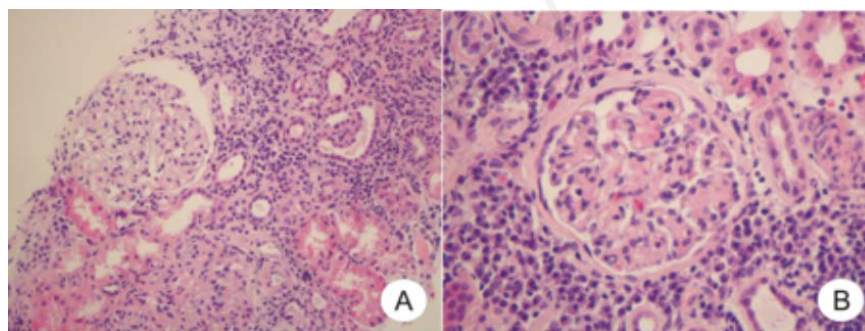
This patient exhibited autoimmune thyroiditis. Thyroid involvement in IgG4-related disease includes Riedel's thyroiditis and a subgroup of Hashimoto's disease. Riedel's

thyroiditis appears with other systemic manifestations of IgG4-related disease. On the contrary, IgG4-Hashimoto's thyroiditis tends to occur as unique and isolated organ involvement.<sup>5</sup> In this case, there were no histological or radiological features associated with IgG4-related disease.<sup>6</sup> In addition, spontaneous improvement prior to treatment with corticosteroids is unusual.

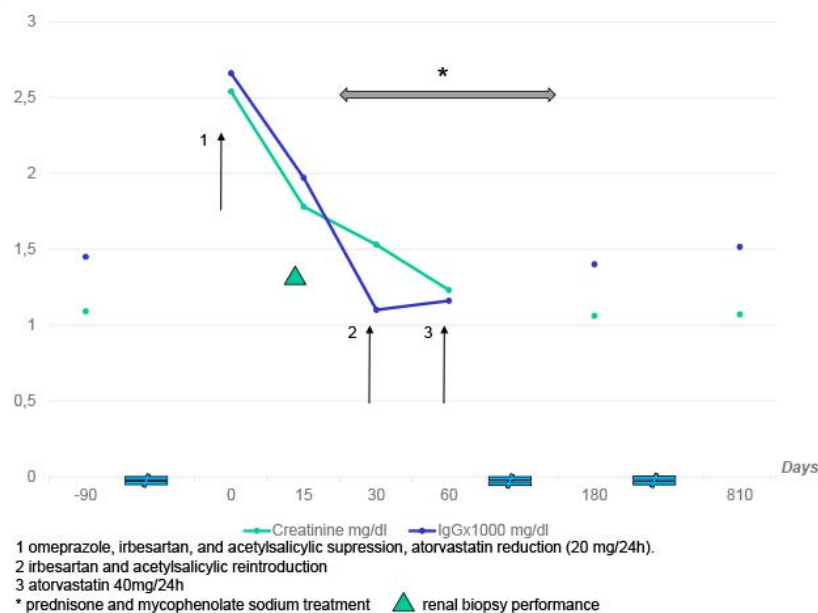
Autoimmune thyroiditis has been associated with ATIN in the context of TINU syndrome.<sup>7</sup> Uveitis in TINU syndrome, which may be subclinical, frequently appears after nephropathy; this manifestation has been reported at 14 and 15 months after nephritis<sup>8,9</sup> but generally arises within 8 months after nephropathy.<sup>8</sup> Therefore, uveitis appearing 12 months after nephritis is atypical for TINU syndrome and does not

permit the definitive diagnosis of this syndrome.<sup>8</sup> In our patient, 3 ocular examinations were performed, the last of which occurred 19 months after diagnosis, and no signs of subclinical uveitis were observed. On the other hand, in this particular patient, the sequential temporal changes in creatinine and IgG serum levels (see comments below and Figure 2) do not support a causal relationship between thyroiditis and ATIN.

When the patient was admitted, omeprazole, irbesartan, and acetylsalicylic acid were discontinued, and the atorvastatin dosage was reduced; her creatinine and IgG then improved. Subsequently, irbesartan and acetylsalicylic acid were reintroduced, and the atorvastatin dosage was increased; these changes did not alter creatinine or IgG. Given all of these findings, we regard



**Figure 1.** Interstitial infiltration composed of plasma cells and lymphocytes with associated tubulitis. (A) Normal glomerulus (Hematoxyline and eosine stain, magnification x200); (B) glomerulus with increase in mesangial matrix (Hematoxyline and eosine stain, magnification x400).



**Figure 2.** Clinical and biochemical course of the patient.

omeprazole as the most probable cause of the patient's ATIN, despite her long period of exposure to this drug.

In ATIN caused by PPIs, the range of exposure to the drug prior to the appearance of ATIN varies, ranging from 10 days to 18 months<sup>10</sup> or even 24 months.<sup>11</sup> Rarely, ATIN caused by PPIs appears when drug dosage is increased; an explanation for this phenomenon is that high plasma levels of a hapten would facilitate its presentation to T lymphocytes.<sup>12</sup> This variability in exposure period and relationship with dosage suggest the involvement of other mechanisms, apart from a T-cell reaction, in PPI-induced ATIN. Ischaemia, which can be associated with age and/or other conditions, reduces peritubular capillary flow, allowing for greater drug/interstitium contact and thereby inducing direct cytotoxicity.<sup>10</sup>

ATIN caused by PPIs occurs mainly in elderly subjects and predominantly involves non-specific symptoms, as observed in this case.<sup>1,10,11,13</sup> Manifestations of hypersensitivity (fever, rash, and eosinophilia) are infrequent.<sup>10,11</sup> The diagnosis of ATIN due to PPIs may be difficult because of the variability in drug exposure times and the predominance of nonspecific manifestations.

Changes in immunological parameters, such as the development of polyclonal hypergammaglobulinaemia<sup>14</sup> and ANCA positivity,<sup>15</sup> have been observed in omeprazole-induced ATIN, suggesting B cell involvement. In this patient, hypergammaglobulinaemia spontaneously diminished within 3 weeks of discontinuing omeprazole and therefore appears to have been dependent on this medication. Although uncommon, hypergammaglobulinaemia has also been reported in ATIN caused by other drugs, such as ibuprofen.<sup>16</sup>

## Conclusions

This case illustrates that ATIN caused by PPIs may appear after a long period of exposure and may be accompanied by analytical anomalies that simulate a systemic disease.

## References

1. Praga M, Sevillano A, Auñón P, González E. Changes in the aetiology, clinical presentation and management of acute interstitial nephritis, an increasingly common cause of acute kidney injury. *Nephrol Dial Transplant* 2015;30:1472-9.
2. Muriithi AK, Leung N, Valeri AM, et al. Biopsy-proven acute interstitial nephritis, 1993-2011: a case series. *Am J Kidney Dis* 2014;64:558-66.
3. Torpey N, Barker T, Ross C. Drug-induced tubulo-interstitial nephritis secondary to proton pump inhibitors: experience from a single UK renal unit. *Nephrol Dial Transplant* 2004;19:1441-6.
4. Moledina DG, Perazella MA. PPIs and kidney disease: from AIN to CKD. *J Nephrol* 2016;29:611-6.
5. Li Y, Zhou G, Ozaki T, et al. Distinct histopathological features of Hashimoto's thyroiditis with respect to IgG4-related disease. *Mod Pathol* 2012;25:1086-97.
6. Tang X, Zhu B, Chen R, et al. Evaluation of diagnostic criteria for IgG4-related tubulointerstitial nephritis. *Diagn Pathol* 2015;10:83.
7. Li C, Su T, Chu R, et al. Tubulointerstitial nephritis with uveitis in Chinese adults. *Clin J Am Soc*

*Nephrol* 2014;9:21-8.

8. Mandeville JT, Levinson RD, Holland GN. The tubulointerstitial nephritis and uveitis syndrome. *Surv Ophthalmol* 2001;46:195-208.
9. Jahnukainen T, Ala-Houhala M, Karikoski R, et al. Clinical outcome and occurrence of uveitis in children with idiopathic tubulointerstitial nephritis. *Pediatr Nephrol* 2011;26:291-9.
10. Simpson IJ, Marshall MR, Pilmore H, et al. Proton pump inhibitors and acute interstitial nephritis: report and analysis of 15 cases. *Nephrology (Carlton)* 2006;11:381-5.
11. Berney-Meyer L, Hung N, Slatter T, et al. Omeprazole-induced acute interstitial nephritis: a possible Th1-Th17-mediated injury? *Nephrology (Carlton)* 2014;19:359-65.
12. Helsby NA, Lo WY, Simpson IJ, et al. Omeprazole-induced acute interstitial nephritis is not related to CYP2C19 genotype or CYP2C19 phenotype. *Br J Clin Pharmacol* 2010;69:516-9.
13. Geevasinga N, Coleman PL, Webster AC, Roger SD. Proton pump inhibitors and acute interstitial nephritis. *Clin Gastroenterol Hepatol* 2006;4:597-604.
14. Fleury D, Storkebaum H, Mougnot B, et al. Acute interstitial nephritis due to omeprazole. *Clin Nephrol* 1995;44:129.
15. Singer S, Parry RG, Deodhar HA, Barnes JN. Acute interstitial nephritis, omeprazole and antineutrophil cytoplasmic antibodies. *Clin Nephrol* 1994;42:280.
16. Singh AK, Colvin RB. Case records of the Massachusetts General Hospital. Weekly clinicopathological exercises. Case 36-2003. A 68-year-old woman with impaired renal function. *N Engl J Med* 2003;349:2055-63.