

Till surgery do us part: unexpected bilateral kissing molars

Narayanankutty Anish,
Velayudhannair Vivek, Sunila Thomas,
Vineet Alex Daniel, Jincy Thomas,
Prasanna Ranimol

Department of Oral Medicine &
Radiology, PMS College of Dental Science
& Research, Trivandrum, Kerala, India

Abstract

The occurrence impacted teeth, single or multiple is very common. But, phenomenon of kissing molars is an extremely rare phenomenon. Mandibular third molars are the most common impacted teeth. Mandibular first or second molars does not share the same frequency of occurrence. But, there are rare cases in which the occlusal surfaces of impacted molars are united by the same follicular space and the roots point in the opposite direction, and are termed as *kissing molars*. Sometimes, these teeth will be associated with pathologies. This article reports a rare case of mandibular bilateral kissing molars.

Introduction

Multiple unerupted teeth are an uncommon condition in which there is more or less permanently delayed eruption of teeth.¹ If the condition occurs due to endocrine dysfunction, proper treatment may result in the eruption of teeth or if associated with cliedocranial dysplasia, then there is no known therapy.¹ In impacted teeth the eruption will be prevented by some physical barrier in the path of eruption.² Their etiology is multifactorial, including lack of space due to crowding of dental arches and premature loss of deciduous teeth.² Rotation of tooth buds also occurs resulting in long axis of tooth not parallel to normal eruption path.² Most frequently impacted teeth are maxillary and mandibular third molars and maxillary cuspids; also mandibular teeth exhibit more severe impaction than maxillary teeth.¹ In cases where the second and third mandibular teeth are impacted, their occlusal surface contacts each other in a single follicular space and roots pointing in opposite direction are called *kissing molars* (KM) or *rosette formation*.^{3,4} This term is also being applied to describe similar conditions involving first and second impacted molars, and has also been associated with mucopolysacchroidoses.⁵

Case Report

A 35-year-old male patient reported to the department of Oral Medicine and Radiology with a chief complaint of dislodged filling on the upper right back tooth since 2 days. No relevant medical history was reported. On extraoral examination, no relevant findings were present. Temporomandibular joint examination also revealed no relevant findings. On intraoral examination, missing teeth were detected in relation to 17, 18, 27, 28, 36, 37, 38, 47 and 48. History of uncomplicated extraction of lower left back tooth 5 years before was reported. Restoration was dislodged in relation to 16. The region of alveolar arch of the missing teeth showed small enlargement. No other symptoms were reported. On palpation, bony hard region were detected in relation to the same area without tenderness or pain. Panoramic radiographs were taken to check the status of teeth (if any) in the regions (Figure 1). It showed multiple impacted molars and an impacted mandibular right canine. No supernumerary tooth was present. But it revealed the presence of impacted second and third molars on right and left quadrants of both maxillary and mandibular dental arches. In mandible, the impacted right and left second and third molars showed their occlusal surfaces contacting each other in same follicular space with roots pointing in opposite directions, *i.e.*, kissing molars. Both right and left impaction showed overlapping of the tooth over mandibular canal. On both right and left sides, the distance between inferior border of mandible and the tooth only about 4 mm. Two occlusal radiographs (true) also were taken for the localization of position of the lower impacted molars, which showed a slight buccal positioning of 37 and 47. No prominent cortical bone expansion was detected on both buccal and lingual side of both mandibular quadrants (Figure 2).

Discussion

Impaction of teeth is a common condition, among which the most commonly impacted tooth third molars.⁶ In cases where the second and third mandibular teeth are impacted, their occlusal surface contacts each other in a single follicular space and roots pointing in opposite direction are called *kissing molars* or *rosette formation*.³ This term is also being applied to describe similar conditions involving first and second impacted molars, and has also been associated with mucopolysacchroidoses.⁵ A thorough literature search revealed only very few reported cases of KM.⁶

The etiology of KM is still unknown.⁷ It has been hypothesized that, resorption of bone by

Correspondence: Velayudhannair Vivek,
Department of Oral Medicine & Radiology, PMS
College of Dental Science & Research, Golden
hills, Vattappara, Venkode PO, Trivandrum, Pin
695028, Kerala, India.
Tel.: 9447341035. E-mail: vivekv@rediffmail.com

Key words: kissing molars, impaction, rosette formation, mandibular.

Contributions: NA, VV, JT, PR, study concept and design; NA, PR, data analysis; NA, VV, PR, statistical analysis; NA, manuscript preparation; All authors are guarantors and contributed in definition of intellectual content, literature search, data acquisition, manuscript editing and review.

Conflict of interests: the authors declare no potential conflict of interests.

Received for publication: 22 July 2014.
Accepted for publication: 3 October 2014.

This work is licensed under a Creative Commons Attribution NonCommercial 3.0 License (CC BY-NC 3.0).

©Copyright: N. Anish et al., 2015
Licensee PAGEPress, Italy
Clinics and Practice 2015; 5:688
doi:10.4081/cp.2015.688

cystic formation can result in bone loss along mesial root of the impacted third molar and cause movement and tipping.⁷ Also presence of a fourth molar (if present) can be a predisposing factor.⁷

According to a study by Aydin *et al.*, 33.3% of the total KM were associated with dentigerous cyst, and suggests that dentigerous cyst formation may inhibit the eruption of first and second molars.⁶ So, histopathological evaluation of soft tissues surrounding the crowns of KM is very essential.⁶ Multiple rosetting of molars could also be associated with mucopolysaccharidoses.⁴ These are inherited metabolic disorders, in which there will be abnormal deposition of mucopolysaccharides in the tissues like, skin, soft tissues of airway, cornea, central nervous system, heart, liver, spleen, bones, ligaments, and other sites due to an enzyme abnormality.⁶ But, this case was a solitary radiological finding and there was no reason for a doubt of mucopolysaccharidoses.

Kissing molars can be classified into 3 types: i) class I (impaction of lower first and second molars); ii) class II (impaction of lower second and third molar); iii) class III (impaction of lower third and fourth molar).⁶ According to this classification, this case may be considered as class II. One of the foremost limitation of this classification is that it does not provide us with details regarding depth of the teeth in bone, angulation of individual teeth in relation to the opposite tooth or to the

inferior border of mandible, buccal or lingual bone coverage, whether in maxilla or mandible (location), approximation to important anatomic structures (*e.g.*, mandibular canal), etc. Hence there is a requirement for a systematic classification system for classifying KM, addressing the above limitation, keeping in view the probable underlying systemic diseases that may alter the diagnostic process and treatment plan.

The occurrence impacted teeth, single or multiple is very common. But, as stated in various literatures, the phenomenon of KM is an extremely rare phenomenon.⁶ When considering study about various impacted teeth,⁶ bilateral occurrence of kissing molars can be considered as the rarest. The dentist must have a thorough knowledge about the various forms of impactions including KM, because these can be signs of various medical conditions. Detailed and specific investigations are further required.

Conclusions

References

1. Rajendran R. Developmental disturbances of oral and paraoral structures. In: Rajendran R, Sivapathasundaram B, eds. *Shafer's textbook of oral pathology*, 7th ed. India: Elsevier; 2012. pp 1-80.
2. Suri L, Gagari E, Vastardis H. Delayed tooth eruption: pathogenesis, diagnosis and treatment. A literature review. *Am J Orthod Dentofacial Orthop* 2004;126:432-45.
3. Van Hoof RF. Four kissing molars. *Oral Surg Oral Med Oral Pathol* 1973;35:284.
4. Boffano P, Galesio C. Kissing molars. *J Craniofacial Surg* 2009;20:1269-70.
5. Krishnan B. Kissing molars. *Br Dental J* 2008;204:281-2.
6. Shahista P, Mascarenhas R, Shetty S, Husain A. Kissing molars: an unusual unexpected impaction. *Archiv Med Health Sci* 2013;1:52-3.
7. Gulses A, Varol A, Senceman M, Dumlu A. A study of impacted love: kissing molars. *OHDM* 2012;11:185-8.

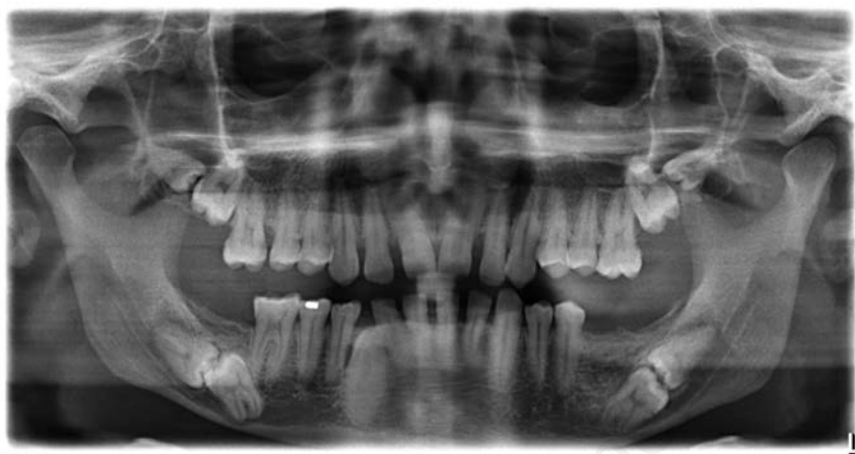

Figure 1. Panoramic radiograph showing bilateral mandibular kissing molars.

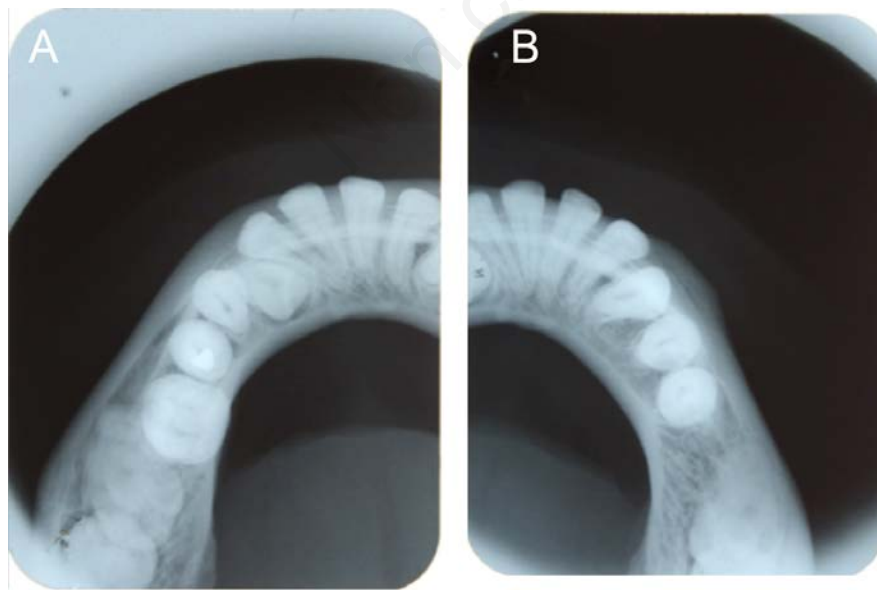


Figure 2. Occlusal radiograph of A) mandibular right quadrant and B) mandibular left quadrant.