

Staphylococcus lugdunensis gluteal abscess in a patient with end stage renal disease on hemodialysis

Mansoor Mehmood, Faisal A. Khasawneh
Section of Infectious Diseases,
Department of Internal Medicine, Texas
Tech University, Health Sciences Center,
Amarillo, TX, USA

Abstract

A 57-year-old end stage renal disease patient on hemodialysis (HD) presented with sepsis secondary to right buttock abscess and overlying cellulitis. She was started on broad-spectrum antibiotic therapy and underwent incision and drainage with marked improvement. Her cultures grew methicillin-resistant *Staphylococcus lugdunensis*. This bacterium is more virulent than other coagulase negative staphylococci and has been implicated in causing a variety of serious infections but it has been underreported as a cause of skin infections in HD patients and possible other patient populations.

Introduction

Traditionally, *Staphylococcus aureus* and streptococci have been the most common culprits in skin and soft tissue infections.¹ Nevertheless, gram-negative bacteria and anaerobes can play a role in certain patient pupations.² Wider use of immunosuppression, bacterial resistance and newly emerging pathogens are changing the landscape of skin and soft tissue infections.³ We report a case of methicillin-resistant *Staphylococcus lugdunensis* skin abscess in a hemodialysis (HD) patient. This bacterium has been rarely implicated in causing skin infections in end stage renal disease (ESRD) patients. The patient provided her consent to publish this case report.

Case Report

A 57-year-old white female with a past medical history significant for ESRD on HD admitted with right buttock abscess with overlying cellulitis. One-week prior, she presented to a local emergency room with right buttock boil. No intervention was undertaken and she was sent home on oral trimethoprim/sulfamethoxa-

zole (TMP/SMX). She did not fill her prescription nor sought further care till this admission. In the emergency room, she complained of fever, chills and throbbing pain at the abscess site. She had no other skin lesions or complaints. The patient's past medical history is significant for hypertension, which led to her ESRD. She has been on HD for 16 years. She did not have recent hospitalization within the past 6 months nor she had history of methicillin - resistant *S. aureus* colonization or infection.

On examination, she was awake and oriented but in obvious pain. She had an oral temperature of 38.6°C. Her heart rate was 112 beats/min and her blood pressure was 118/62 mmHg. Her heart, lung and abdominal examination were unremarkable. She had a right-sided femoral arterio-venous graft with a strong thrill and no overlying redness. This arterio-venous graft was placed 2 years ago, after she ran out of upper body HD access sites. Her right buttock showed a warm, tender, fluctuant area with surrounding redness. There were no other skin lesions. She was admitted with sepsis secondary to a complicated right buttock skin infection. She was started empirically on ceftaroline (600 mg intravenously once then 200 mg every 12 h) for her complicated skin infection and the surgical service consulted.

Blood testing showed a white blood cell count of $36.9 \times 10^9/L$, hemoglobin of 11.1 g/dL and creatinine of 4.8 mg/dL. Electrolytes and liver function tests were within normal limits. Non-contrast computed tomography scans of the pelvis showed right buttock cellulitis with few gas bubbles in the soft tissues (Figure 1).

The patient underwent incision and drainage of the right buttock abscess. Her blood cultures were negative but purulent secretions from the right buttock grew *S. lugdunensis*. Transthoracic echocardiography was negative for valvular vegetations. The bacterium was methicillin-resistant but was susceptible to vancomycin, ciprofloxacin, clindamycin, erythromycin, TMP/SMX, tetracycline, rifampin and linezolid. Bacterial identification was performed by Microscan WalkAway plus system (Siemens, Berlin-Munich, Germany). Her condition improved markedly with the subsequent initiation of negative pressure wound therapy (Figure 2). On the 11th hospital day, she was discharged home to finish 2 more weeks of oral doxycycline (100 mg every 12 h). The patient was followed in the outpatient clinic and showed complete healing of her infection.

Discussion

We presented a case of skin abscess caused

Correspondence: Faisal A. Khasawneh, Section of Infectious Diseases, Department of Internal of Medicine, Texas Tech University Health Sciences Center, 1400 S. Coulter Street Amarillo, TX 79106, USA.
Tel.: +1.806.354.5480 - Fax: +1.806.354.5765.
E-mail: faisal.khasawneh@ttuhsc.edu

Key words: *Staphylococcus lugdunensis*, hemodialysis, skin abscess.

Conflict of interest: all authors have no conflict of interest to report.

Contributions: FAK diagnosed and treated the patient. MM reviewed the patient's data and the literature and he wrote the manuscript's initial draft. FAK reviewed the literature and edited the manuscript. All authors read and approved the manuscript.

Received for publication: 2 September 2014.
Revision received: 8 October 2014.
Accepted for publication: 12 November 2014.

This work is licensed under a Creative Commons Attribution NonCommercial 3.0 License (CC BY-NC 3.0).

©Copyright M. Mehmood and F.A. Khasawneh, 2015
Licensee PAGEPress, Italy
Clinics and Practice 2015; 5:706
doi:10.4081/cp.2015.706

by *S. lugdunensis* in a HD patient. Although this bacterium belongs to coagulase negative staphylococci (CoNS), its role in this infection is indisputable given the fact that it was the only bacterium grew in the surgical cultures. ESRD patients have impaired immunity and are at risk for different types of infections including skin infections.⁴ *S. aureus* is a notorious pathogen causing skin infections in ESRD patients meanwhile *S. lugdunensis* skin infections have been rarely reported in this patient population.

S. lugdunensis, described first in 1988, is a CoNS and part of the normal skin flora.² It is much more virulent than other CoNS and has been implicated in causing multiple infections including infective endocarditis, osteomyelitis, septic arthritis and skin and soft tissue infections.⁵⁻⁸

S. lugdunensis virulence is of notice and in many ways it mirrors that of *S. aureus*.⁹ Although it doesn't carry the genes for producing enterotoxins A, B and C or toxic shock syndrome toxin or exfoliative toxin, it produces other types of toxins that account for its pathogenicity.⁹ To date, the full spectrum of mechanisms by which it causes severe infections is not completely understood and is still being investigated.

Identifying *S. lugdunensis* in the clinical microbiology lab can be challenging.^{10,11} The

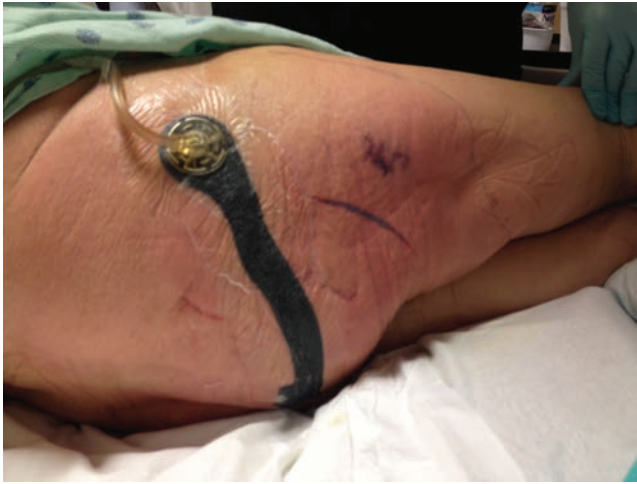

Figure 1. The patient's right buttock showing residual cellulitis after surgical debridement and negative wound therapy implementation.

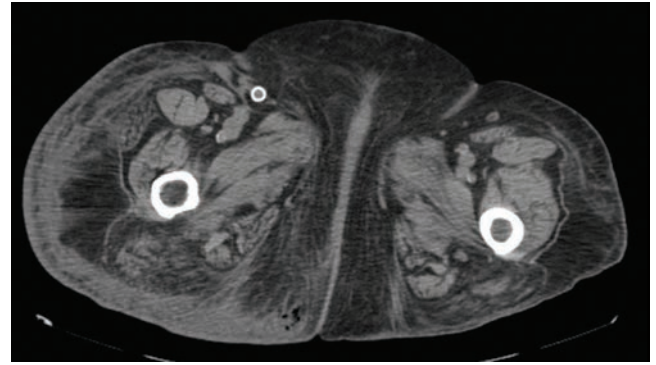


Figure 2. Computed tomography cross-section of the pelvis showing right buttock inflammatory changes and a subcutaneous pocket of air lateral to the natal cleft. The pocket of air corresponds to the described abscess.

chemical reactions considered crucial to differentiate it from other staphylococci, namely; clumping factor, ornithine decarboxylase and pyrrolidonyl arylamidase, are not foolproof and multiple studies reported those tests to be falsely negative.^{12,13} Furthermore, some commercially available automated phenotypic identification systems have been found to misidentify *S. lugdunensis* in up to 50% of cases.¹⁰ We speculate that the above could have accounted for the underreporting of this bacterium as a culprit in skin infections in HD patients and other patient populations. Hence, astute clinicians need to consider *S. lugdunensis* in any unexpectedly severe infection caused by CoNS. Molecular analysis like ribotyping and genotyping might be of help in such circumstances. Unfortunately, the latter tests are not available in many community-hospital's clinical labs including ours.

The frequency of isolating *S. lugdunensis* among CoNS from clinical specimens varies from one locale to another and ranges between 1% and 7%.^{11,14-17} The largest case series reported clinical and microbiological data for 20 patients with skin infection caused by this bacterium.¹⁸ The frequency of skin infections caused by *S. lugdunensis* in that hospital was 0.42%. The mean age of the cohort was 47.3 years (range 16-77 years); 11 were female (55%). *S. lugdunensis* was the only pathogen isolated in 15 of the 20 specimens (75%). Underlying diseases were present in 13 patients (65%) and the most commonly reported ailments were diabetes and obesity, neither of which was present in our patient. One patient had chronic kidney disease but was not on HD. Breast, abdominal wall and lower limbs

were the most commonly involved locations. All of the 20 isolates were methicillin-susceptible.

The second largest case series described 16 patients with skin infections caused by *S. lugdunensis*.¹⁹ In that hospital, CoNS was isolated in 1100 clinical specimens, of which 25 (2.27%) were identified as *S. lugdunensis* and 16 of the latter were incriminated pathogens in skin infections. The mean age of that cohort was 48.5 years (range 29-65 years); 7 were female (43.8%). Most commonly reported risk factors in this group were diabetes and breast disease. None of the patients was on HD. Breast, abdomen, perineum and lower limbs were the most commonly involved areas. None of the 16 isolates was methicillin-resistant.

Of note, *S. lugdunensis* was rarely implicated in causing HD and peritoneal dialysis catheters' exit-site and tunnel infections.^{20,21} Unlike our case, neither bacterium was methicillin-resistant and both infections developed in the presence of hardware, the catheter.

Upon reviewing the above literature the following was noticeable: i) *S. lugdunensis* causes a variety of suppurative skin infections including abscesses and surgical site infections; ii) patients' ages varied and there was no gender predilection; iii) diabetes, obesity and breast disease were the most commonly reported risk factors. Of note, none of the reported patients in the above case series was on HD; iv) breast, abdominopelvic area and lower limbs were the most commonly involved areas; v) like *S. aureus*, *S. lugdunensis* skin infections are monomicrobial in many cases; vi) methicillin-resistant *S. lugdunensis* skin infections are uncommon. The prevalence of methicillin-resistance among *S. lugdunensis* isolates of all

sources is less than 10%.⁷ Other CoNS, especially *S. epidermidis*, are notorious for being methicillin-resistance and we speculate that this mechanism of resistance was acquired from these bacteria given they are all skin colonizers; vii) none of the reported cases died.

Conclusions

Our case, underscores the potential emergence of *S. lugdunensis* as a cause of skin infections in HD patients. Unexpectedly severe infection caused by CoNS should trigger further testing to ascertain the exact species of that bacterium. Further work is needed to identify this bacterium mechanism of transmission, virulence factors, spectrum of disease and best antimicrobial therapy.

References

1. Pallin DJ, Espinola JA, Leung DY, et al. Epidemiology of dermatitis and skin infections in United States physicians' offices, 1993-2005. *Clin Infect Dis* 2009;49:901-7.
2. Stevens DL, Bisno AL, Chambers HF, et al. Practice guidelines for the diagnosis and management of skin and soft tissue infections: 2014 update by the Infectious Diseases Society of America. *Clin Infect Dis* 2014;59:e10-52.
3. Edelsberg J, Taneja C, Zervos M, et al. Trends in US hospital admissions for skin and soft tissue infections. *Emerg Infect*

- Dis 2009;15:1516-8.
4. Dalrymple LS, Go AS. Epidemiology of acute infections among patients with chronic kidney disease. *Clin J Am Soc Nephrol CJASN* 2008;3:1487-93.
 5. Babu E, Oropello J. *Staphylococcus lugdunensis*: the coagulase-negative staphylococcus you don't want to ignore. *Exp Rev Anti-infect Ther* 2011;9:901-7.
 6. Bocher S, Tønning B, Skov RL, Prag J. *Staphylococcus lugdunensis*, a common cause of skin and soft tissue infections in the community. *J Clin Microbiol* 2009;47: 946-50.
 7. Klotchko A, Wallace MR, Licitra C, Sieger B. *Staphylococcus lugdunensis*: an emerging pathogen. *Southern Med J* 2011;104:509-14.
 8. Vandenesch F, Eykyn SJ, Etienne J, Lemozy J. Skin and post-surgical wound infections due to *Staphylococcus lugdunensis*. *Clin Microbiol Infect* 1995;1:73-4.
 9. Ravaioli S, Selan L, Visai L, et al. *Staphylococcus lugdunensis*, an aggressive coagulase-negative pathogen not to be underestimated. *Int J Artif Organs* 2012;35:742-53.
 10. Kim M, Heo SR, Choi SH, et al. Comparison of the MicroScan, VITEK 2, and Crystal GP with 16S rRNA sequencing and MicroSeq 500 v2.0 analysis for coagulase-negative *Staphylococci*. *BMC Microbiol* 2008;8:233.
 11. Shin JH, Jung HJ, Lee HR, et al. Prevalence, identification, and antimicrobial susceptibility of *Staphylococcus lugdunensis* from various clinical specimens in Korea. *Jpn J Infect Dis* 2007;60:312-3.
 12. Mateo M, Maestre JR, Aguilar L, et al. Genotypic versus phenotypic characterization, with respect to susceptibility and identification, of 17 clinical isolates of *Staphylococcus lugdunensis*. *J Antimicrob Chemother* 2005;56:287-91.
 13. Pinsky BA, Samson D, Ghafghaichi L, et al. Comparison of real-time PCR and conventional biochemical methods for identification of *Staphylococcus lugdunensis*. *J Clin Microbiol* 2009;47:3472-7.
 14. Jarlov JO, Højbjerg T, Busch-Sørensen C, et al. Coagulase-negative *Staphylococci* in Danish blood cultures: species distribution and antibiotic susceptibility. *J Hospital Infect* 1996;32:217-27.
 15. Choi SH, Chung JW, Lee EJ, et al. Incidence, characteristics, and outcomes of *Staphylococcus lugdunensis* bacteremia. *J Clin Microbiol* 2010;48:3346-9.
 16. Kawamura Y, Hou XG, Sultana F, et al. Distribution of *Staphylococcus* species among human clinical specimens and emended description of *Staphylococcus caprae*. *J Clin Microbiol* 1998;36:2038-42.
 17. De Paulis AN, Predari SC, Chazarreta CD, Santoianni JE. Five-test simple scheme for species-level identification of clinically significant coagulase-negative staphylococci. *J Clin Microbiol* 2003;41:1219-24.
 18. Arias M, Tena D, Apellaniz M, et al. Skin and soft tissue infections caused by *Staphylococcus lugdunensis*: report of 20 cases. *Scand J Infect Dis* 2010;42:879-84.
 19. Papapetropoulos N, Papapetropoulou M, Vantarakis A. Abscesses and wound infections due to *Staphylococcus lugdunensis*: report of 16 cases. *Infection* 2013;41:525-8.
 20. Koch LD, Knoll F, Hartmann G, Lhotta K. Recurrent exit-site infection due to *Staphylococcus lugdunensis* - a virulent coagulase-negative *Staphylococcus*. *Peritoneal Dialysis Int* 2011;31:372-3.
 21. Schnitzler N, Meilicke R, Conrads G, et al. *Staphylococcus lugdunensis*: report of a case of peritonitis and an easy-to-perform screening strategy. *J Clin Microbiol* 1998;36:812-3.