

Primary retroperitoneal mucinous cystic tumors with borderline malignancy: a case report and literature review

Megumi Manrai,¹ Naoki Takesita,¹ Hiroaki Ishida,¹ Akiko Takashima,¹ Tomohiro Adachi,¹ Izumi Sasaki,¹ Kei Yokokawa,¹ Wataru Tokuyama,² Nobuyuki Hiruta,² Toshihiko Kinoshita¹

¹Department of Obstetrics and Gynecology; ²Department of Pathology, Toho University Medical Center-Sakura Hospital, Chiba, Japan

Abstract

Primary retroperitoneal mucinous cystic tumors with borderline malignancy are rarely encountered. To date, only 12 cases have been reported in the literature. In this report, we present an additional case. A 65-year-old nulliparous woman complained of abdominal fullness. Her medical history included a hysterectomy and a single salpingo-oophorectomy performed 25 years prior to the present event. Physical examination revealed a large cystic mass in the abdomen and pelvis. During laparotomy, a cystic tumor measuring 21×14 cm in size was observed in the left retroperitoneal space. The tumor was resected, and the final diagnosis was primary retroperitoneal mucinous cystic cancer with borderline malignancy.

Introduction

Primary retroperitoneal mucinous cystic tumors with borderline malignancy (PRMCs-BM) are rare.¹ Although they resemble ovarian mucinous neoplasms, they have been reported in women with normal ovaries.² There is no consensus regarding their genesis, and because of their extreme rarity, their histogenesis, biological behavior, and optimal management strategy remain speculative. We herein describe a case of a PRMC-BM and review the pertinent literature.

Case Report

A 65-year-old nulliparous woman was referred to our department for abdominal distention. Her medical history included a hys-

terectomy for leiomyoma at 40 years of age. She also underwent a single salpingo-oophorectomy at the same time, although no further information about this operation was available. Pelvic examination revealed a soft tumor extending from the pelvis to the left abdominal cavity. Ultrasonography of the pelvis confirmed the presence of a large multilocular cystic mass measuring 20 cm in size (Figure 1A). Subsequent magnetic resonance imaging (MRI) revealed a rounded cystic lesion that filled almost the entire pelvis (Figure 1B). Her serum cancer antigen 125 level was within the normal range. Hormonal tests were not performed.

The preoperative diagnosis was a cyst of the left ovary. An exploratory laparotomy was performed to further evaluate the mass, which was located in the left retroperitoneal space with no connection to other intra- or extra-abdominal organs. It was then completely resected without any complication. The tumor did not spread into the abdominal cavity.

Gross pathological examination revealed a thinly capsulated, multilocular cystic mass containing mucoid material and measuring 21×14 cm in diameter (Figure 2A). Small papillary areas were noted inside the cyst wall. Histologically, a single layer of both endocervical-like and intestinal-type columnar cells without atypia lined the cyst wall (Figure 2B). In the papillary area of the tumor, the cells displayed mild to moderate nuclear atypia and stratification of two to three layers but no stromal invasion (Figure 2C). Ovarian tissue was not observed.

The final diagnosis was PRMC-BL. At her 1-year follow-up, the patient remained free of disease.

Discussion

PRMCs are uncommon neoplasms that occur almost exclusively in women, with only three cases reported in men.²⁻⁴ There are three clinicopathologic types of PRMCs: mucinous cystadenoma, PRMC-BM, and mucinous cystadenocarcinoma. We performed a literature review of PRMC-BM using MEDLINE® and identified only 12 cases from 11 reports published since 1988 (Table 1).^{1,3,5-13} Therefore, the incidence of PRMC-BM is extremely rare.

In previous reports of PRMC-BM, most patients were asymptomatic or experienced mild symptoms of distention, and pain owing to the mass was rare. The tumors were relatively large, ranging from 10 cm to >20 cm in diameter, and they were large enough to cause symptoms such as abdominal fullness.¹⁰ Preoperative diagnosis of PRMC-BM is very difficult, because not only are the tumors often overlooked in differential diagnoses but also

Correspondence: Toshihiko Kinoshita, Department of Obstetrics and Gynecology, Toho University Medical Center Sakura Hospital, 564-1 Shimoshizu Sakura City, Chiba 285-8741, Japan. Tel.: +81.43.462.8811 - Fax: +81.43.462.8820. E-mail: kino@sakura.med.toho-u.ac.jp

Key words: retroperitoneal neoplasm, mucinous cystadenoma, borderline malignancy.

Contributions: all authors contributed to the design and performance of the research project and manuscript writing. MM wrote the manuscript; NT critically revised the manuscript; HI, AT, TA, IS KY, WT, NH, and TK participated in the case diagnosis and treatment.

Conflict of interest: the authors declare no potential conflict of interests.

Received for publication: 15 October 2014.

Revision received: 13 December 2014.

Accepted for publication: 17 December 2014.

This work is licensed under a Creative Commons Attribution NonCommercial 3.0 License (CC BY-NC 3.0).

©Copyright M. Manrai et al., 2015
Licensee PAGEPress, Italy
Clinics and Practice 2015; 5:722
doi:10.4081/cp.2015.722

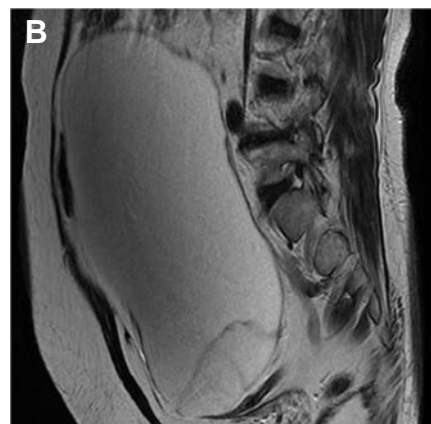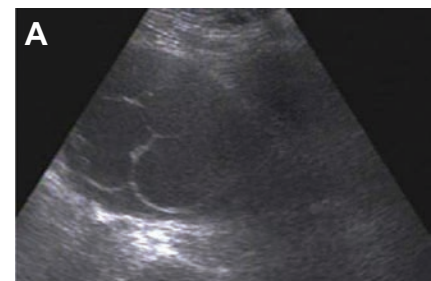


Figure 1. A) An ultrasonography image of the pelvis shows a large multicystic mass. B) A magnetic resonance image of the pelvis shows a large multicystic mass.

there are no available sensitive methods or reliable markers.⁸ As retroperitoneal mucinous tumors are histologically similar to ovarian mucinous cystadenomas, ultrasonography, computed tomography, and MRI are usually not useful for distinguishing between them.¹⁰ Although aspiration is a good method for delineating the nature of the cyst, cytologic analysis of the aspirated fluid frequently fails to reveal the type of epithelial cells lining the cyst. Therefore, exploratory laparotomy with complete excision of the cyst is usually indicated for both the diagnosis and treatment of PRMC-BM.⁸ Retroperitoneal mucinous tumors of epithelial origin are rare because epithelial cells do not normally exist in the peritoneum; therefore, their origin has been debated. Several hypotheses have been proposed to explain their genesis. The majority of these hypotheses suggest that they arise either from ectopic ovarian tissue in teratomas in which the mucinous epithelium has overridden all other components to become the only identifiable component, or from intestinal duplication,

also known as enterogenous genesis.^{10,14} PRMCs are histologically similar to mucinous cystadenomas found in the ovaries. However, ovarian tissue has been observed in only one reported case of PRMC,¹⁵ and it was not observed in the present case. Furthermore, PRMCs have been previously reported in men. These findings exclude heterotopic ovarian tissue as the origin of PRMCs. Enterogenous genesis from intestinal duplication can also be excluded owing to the lack of well-developed intestinal mucosa and smooth muscles in PRMCs. The possibility of a monodermal variant of teratoma is unlikely because of the lack of other tissue types or typical structures of teratomas in PRMCs.^{8,10}

A PRMC tumor should be treated in the same manner as a primary ovarian tumor of similar grade and comparable stage. In previously described cases of PRMC-BM, only tumor resection was performed, and no recurrence or metastasis was reported.¹⁰ Therefore, the long-term prognosis of PRMC-BM seems to be quite good as no evidence of disease was observed

even after a follow-up period of up to 148 months.¹³ In the present case, we followed the patient every 6 months with pelvic ultrasonography examination. Her post-operative pelvic imaging showed no abnormalities, and her serum cancer antigen 125 levels remained within the normal range. Because of the small number of PRMC-BM cases reported in the international literature, investigators cannot justify the use of any adjuvant chemotherapy protocols. Surgery seems to be sufficient for the treatment of PRMC, especially if there is no eruption of the capsule in the cystadenoma. Some authors recommend chemotherapy for the treatment of PRMC cystadenomas and cystadenocarcinomas because their mechanisms of histogenesis may be the same as those of mucinous tumors of the ovaries.^{16,17} The small number of globally registered cases, the insufficient amount of surveillance data, and mainly, the inability to identify patients at a high risk of recurrence support the need for effective registration and further study of these rare tumors.¹⁸

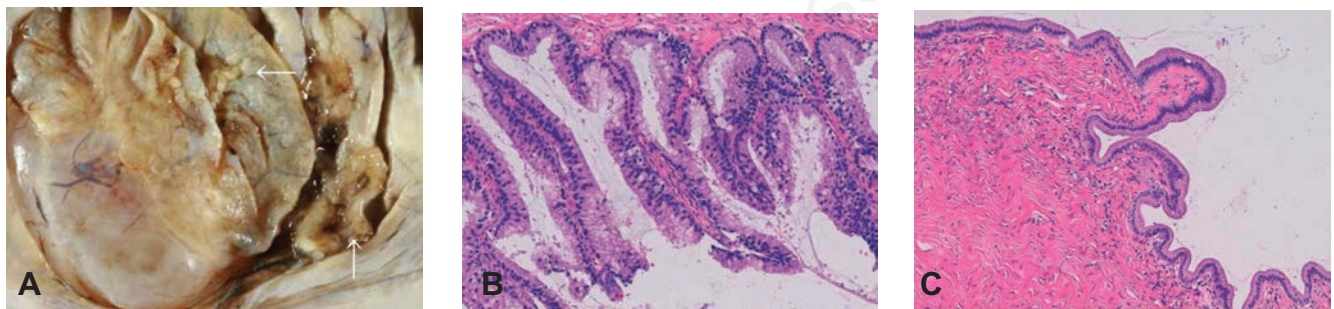


Figure 2. A) The tumor measured 21×14 cm. A cut surface shows a mucinous tumor with focal papillary areas (arrows). B) A photomicrograph of the cystic area of the tumor. The cyst wall was covered with a single layer of columnar mucinous cells without atypia (hematoxylin and eosin staining, ×40). C) A photomicrograph of the papillary area. The tumor cells had tubular structures, and the cells displayed nuclear atypia with stratification but without stromal invasion (hematoxylin and eosin staining, ×200).

Table 1. Cases of primary retroperitoneal mucinous cystic tumors with borderline malignancy reported in the literature since 1988.

Author	Year	Age (years)	Treatment	Origin
Banerjee <i>et al.</i> ⁵	1988	58	TR splenectomy Left adrenalectomy	Unknown
Motoyama <i>et al.</i> ³	1994	42	TR	NED
Pearl <i>et al.</i> ⁶	1996	33	TR	NED, 10 mo
Papadogiannakis <i>et al.</i> ⁷	1997	33	TR	NED, 12 mo
Chen <i>et al.</i> ⁸	1998	48	LR	NED, 12 mo
Gutsu <i>et al.</i> ⁹	2003	41	TR	NED, 18 mo
Matsubara <i>et al.</i> ¹⁰	2005	36	TR	NED, 6 mo
Bakker <i>et al.</i> ¹	2007	45	TR	NED, 12 mo
Cottrill <i>et al.</i> ¹¹	2007	22	TR	-
Bifulco <i>et al.</i> ¹²	2008	35	TR	NED, 24 mo
Roma <i>et al.</i> ¹³	2009	25 43	TR	NED, 148 mo NED, 1 mo
Present case	2014	65	TR	NED, 12 mo

TR, tumor resection; LR, laparoscopic resection; NED, no evidence of disease; mo, months.

Conclusions

In our case, no recurrence was observed during a follow-up period of 12 months. As there are no clear recommendations for surveillance of patients with PRMC-BM, we propose clinical examinations and ultrasonography every 6 months, as well as imaging studies every year using either MRI or computed tomography.

References

- Bakker RF, Stoot JH, Blok P, Merkus JW. Primary retroperitoneal mucinous cystadenoma with sarcoma-like mural nodule: a case report and review of the literature. *Virchows Arch* 2007;451:853-7.
- Green JM, Bruner BC, Tang WW, Orihuela E. Retroperitoneal mucinous cystadenocarcinoma in a man: case report and review of the literature. *Urol Oncol* 2007;25:53-5.
- Motoyama T, Chida T, Fujiwara T, Watanabe H. Mucinous cystic tumor of the retroperitoneum. A report of two cases. *Acta Cytol* 1994;38:261-6.
- Thamboo TP, Sim R, Tan SY, Yap WM. Primary retroperitoneal mucinous cystadenocarcinoma in a male patient. *J Clin Pathol* 2006;59:655-7.
- Banerjee R, Gough J. Cystic mucinous tumours of the mesentery and retroperitoneum: report of three cases. *Histopathology* 1988;12:527-32.
- Pearl ML, Valea F, Chumas J, Chalas E. Primary retroperitoneal mucinous cystadenocarcinoma of low malignant potential: a case report and literature review. *Gynecol Oncol* 1996;61:150-2.
- Papadogiannakis N, Gad A, Ehliar B. Primary retroperitoneal mucinous tumor of low malignant potential: histogenetic aspects and review of the literature. *APMIS* 1997;105:483-6.
- Chen JS, Lee WJ, Chang YJ, et al. Laparoscopic resection of a primary retroperitoneal mucinous cystadenoma: report of a case. *Surg Today* 1998;28:343-5.
- Gutsu E, Mishin I, Gagauz I. Primary retroperitoneal mucinous cystadenoma. A case report and brief review of the literature. *Zentralbl Chir* 2003;128:691-3 [in German].
- Matsubara M, Shiozawa T, Tachibana R, et al. Primary retroperitoneal mucinous cystadenoma of borderline malignancy: a case report and review of the literature. *Int J Gynaecol Pathol* 2005;24:218-23.
- Cottrill HM, Roberts WS. Primary retroperitoneal mucinous borderline tumor: a case report. *Gynecol Oncol* 2007;106:626-7.
- Bifulco G, Mandato VD, Giampaolino P, et al. Huge primary retroperitoneal mucinous cystadenoma of borderline malignancy mimicking an ovarian mass: case report and review. *Anticancer Res* 2008;28:2309-15.
- Roma AA, Malpica A. Primary retroperitoneal mucinous tumors: a clinicopathologic study of 18 cases. *Am J Surg Pathol* 2009;33:526-33.
- Yang DM, Jung DH, Kim H, et al. Retroperitoneal cystic masses: CT, clinical, and pathologic findings and literature review. *Radiographics* 2004;24:1353-65.
- Pennell TC, Gusdon JP Jr. Retroperitoneal mucinous cystadenoma. *Am J Obstet Gynecol* 1989;160:1229-31.
- Fujii S, Konishi I, Okamura H, Mori T. Mucinous cystadenocarcinoma of the retroperitoneum: a light and electron microscopic study. *Gynecol Oncol* 1986;24:103-12.
- de León DC, Pérez-Montiel D, Chanona-Vilchis J, et al. Primary retroperitoneal mucinous cystadenocarcinoma: report of two cases. *World J Surg Oncol* 2007;5:5.
- Mikami M, Tei C, Takehara K, et al. Retroperitoneal primary mucinous adenocarcinoma with a mural nodule of anaplastic tumor: a case report and literature review. *Int J Gynecol Pathol* 2003;22:205-8.