

## Surgical removal of an unrecognized tapestry needle from the urethra

Mustafa Zafer Temiz,<sup>1</sup> Emrah Yuruk,<sup>2</sup>  
Kutlu Teberik,<sup>1</sup> Engin Kandirali<sup>2</sup>

<sup>1</sup>Department of Urology, Bitlis State Hospital, Bitlis; <sup>2</sup>Department of Urology, Bagcilar Training and Research Hospital, Istanbul, Turkey

### Abstract

The variety of intraurethral foreign bodies has been reported in literature. Most of them tend to be self-inserted because of sexual or erotic reasons. We report a 23-year old male patient who had tapestry needle into his urethra, which was not self-inserted. The patient was referred to our institution with dysuria and hematuria. There was microscopic hematuria in urine analysis and no pathologic sign in sonography. The needle was detected in proximal urethra in pelvic X-ray and endoscopic visualization revealed that it was trapped in mucosa. The needle was successfully removed by open surgery. Main treatment for the removal of urethral foreign bodies is usually endoscopic but open surgery may be required in some cases especially cutting foreign bodies.

### Introduction

Presence of a foreign body in the urethra is a urologic emergency and it should always be treated properly. Urethral foreign bodies are relatively rare compared to the prevalence of other foreign bodies in the adult. Underlying psychiatric conditions are commonly found in the urethral foreign body cases.<sup>1</sup>

Most of the intraurethral foreign bodies tend to be self-inserted because of sexual or erotic reasons primarily during states of pathological masturbation, substance abuse and intoxication or as a result of psychological disorders.<sup>2</sup> Presentation is usually with dysuria, hematuria, urinary retention, penile pain or swelling and fevers.<sup>2</sup> We report a 23-year old male patient with tapestry needle into his urethra who was unaware of how did it occur.

To our knowledge, our patient is the first case of intraurethral tapestry needle, which was not self-inserted in adults.

### Case Report

#### History and clinic

A 23-year old male patient was referred to

our clinic with complaints of dysuria and intermittent macroscopic hematuria for the last month. He had a past medical history of muscular dystrophy without treatment and no previous surgical procedure.

#### Examination

Penile skin and urethral meatus was normal. There was no palpable substance suggestive substance of a stone in urethra. The perineal skin was also normal and there was no inflammation or infection sign.

#### Biology and radiology

There was microscopic hematuria in urine analysis and no pathologic sign in sonography. In pelvic X-ray a five centimeters long tapestry needle was detected in the proximal penile urethral localization and it was confirmed with retrograde urethrography (Figure 1).

#### Cystourethroscopy

Cystourethroscopy was performed to the patient in lithotomy position under spinal anesthesia. It revealed the needle was trapped in bulbous urethral mucosa (Figure 2A). The needle was right in front of the external urethral sphincter and featheredge of it was in the sphincteric area (Figure 2B). Because of this dangerous localization of the needle, we planned to open surgery for removal of it.

#### Surgery

The perineal skin incision was preferred because of posterior urethral localization of the needle in endoscopic visualization. Under the fluoroscopic visualization, localization of the needle was identified at lithotomy position and a three centimeters long perineal skin

Correspondence: Mustafa Zafer Temiz, Department of Urology, Bitlis State Hospital, Besminare Mahallesi 13000, Besminare/Bitlis, Turkey. Tel.: +90.434.246.84.20, Fax: +90.434.246.84.24. E-mail: dr\_mustafazafertemiz@hotmail.com

Key words: Urethra; foreign body; tapestry needle.

Acknowledgements: the authors thank to EC Serefoglu MD FECSM, a native speaker for language correction.

Contributions: MZT, study concept and design; EK, manuscript supervision and preparation; MZT, KT, patient management, data organizing and reporting; MZT, EY, literature search; EY, EK, manuscript final version reworking.

Conference presentation: the paper has already been presented in 23<sup>rd</sup> National Turkish Urology Congress, 16-19 October 2014, Antalya, Turkey.

Conflict of interest: the authors declare no potential conflict of interest.

Received for publication: 5 December 2014.

Revision received: 24 February 2014.

Accepted for publication: 16 April 2014.

This work is licensed under a Creative Commons Attribution NonCommercial 3.0 License (CC BY-NC 3.0).

©Copyright M.Z. Temiz et al., 2015  
Licensee PAGEPress, Italy  
*Clinics and Practice* 2015; 5:740  
doi:10.4081/cp.2015.740

incision in front of needle projection was performed. Obtuse end of the needle was palpated in corpus spongiosum after the incision. A

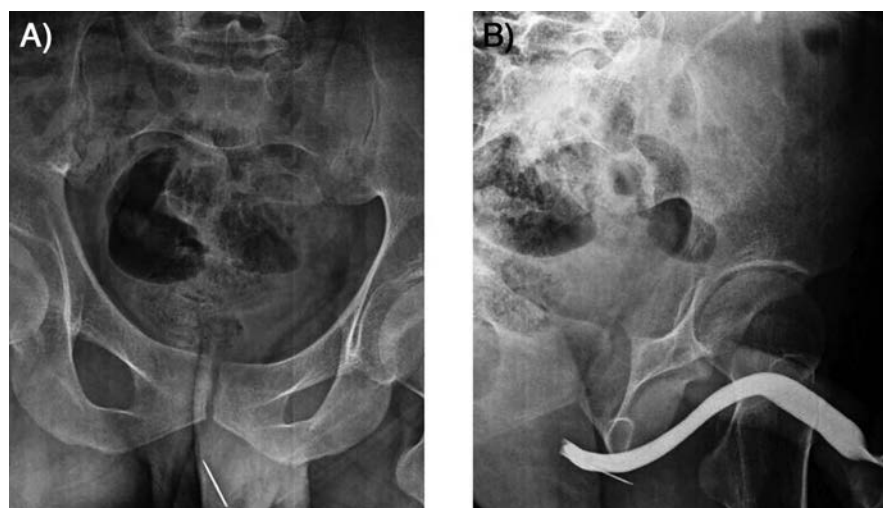


Figure 1. Tapestry needle is at proximal penile urethral localization in pelvic X-ray graph (A) and it was confirmed with retrograde urethrography (B).

one-centimeter incision of corpus spongiosum was performed and the needle was successfully removed with mosquito clamp with minimal damage. There was no iatrogenic injury in the urethra and there was only a 5 mm hole after the extraction of needle. Corpus spongiosum was repaired with 2/0 vicryl following insertion of an 18 F Foley catheter. The skin was repaired with 4/0 rapid vicryl.

There were no complications in the postoperative period. The tetanus prophylaxis was performed and patient was discharged on first day after the operation. The urethral catheter was removed 7 days postoperatively and first month follow-up revealed normal voiding.

The patient questioned about how happened the entrance of tapestry needle into his urethra. Patient had no self-insertion of it in his history and he was sure.

## Discussion

A variety of foreign bodies has reported in literature foreign bodies stuck in the urethra such as needles, pencils, ball point pens, pen lids, garden wire, copper wire, speaker wire, safety pins, Allen keys, wire-like objects (telephone cables, rubber tubes, feeding tubes, straws, string), toothbrushes, household batteries, light bulbs, marbles, cotton tip swabs, plastic cups, thermometers, plants and vegetables (carrot, cucumber, beans, hay, bamboo sticks, grass leaves), parts of animals (leeches, squirrel tail, snakes, bones), toys, pieces of latex gloves, blue tack, intrauterine contraceptive devices (IUCD), tampons, pessaries, cocaine powder, and fluids such as glue and hot wax.<sup>3,4</sup> They are usually self-inserted into genito-urinary tract and commonly occurred in a sexual or erotic activity or similar.<sup>2</sup>

Accidental and iatrogenic foreign bodies occur much more rarely.<sup>5</sup> Wykes *et al.*<sup>6</sup> reported

the accidentally ingested duck bone as a urethral foreign body and they conclude that it may have caused the vesicocolic fistula or may merely have passed through a fistula caused by diverticulitis. Another interesting case included an arrowhead as urethral foreign body was reported by Carruthers.<sup>7</sup> In this report, the arrowhead was inserted on the purpose of punishment by the patient's wife. Other accidental urethral foreign body objects included: magnets, female catheter, urinary incontinence devices and part of a Foley catheter.<sup>5</sup> The iatrogenic urethral foreign body objects included the tip of prostatic resection loop; synthetic slings and a reservoir from an inflatable penile implant are commonly seen after pelvic or genitourinary surgical procedures.<sup>5,8,9</sup>

Delayed treatment of foreign bodies can cause chronic conditions, such as repeated infections, urethritis, urethral rip secondary to periurethral abscess and/or fistula, hemorrhage, and urethral diverticuli.<sup>10</sup>

Initially, a good history should be taken and investigation of a possible foreign body should be done by X-ray, ultrasonography or sometimes by computed tomography scan and cystourethroscopy.<sup>9,11</sup> Comprehensive taken history is an important part of the diagnostic approaches for suspected iatrogenic foreign bodies. Some patients may inform the urethral self-insertion of an object that could lead to a fast diagnosis. The fact that most patients hide the self insertion or forget an accidental entrance that could be happen months or years ago, so evocative questions must put to patient and be stated that self insertion is not an insulting behavior. When we question if our patient is hiding, he refused surely the self-insertion. The patient remembered that suddenly occurred perineal pain whilst sitting on sofa a few months ago at home after detailed questioning. So, we think that the accidental entrance of the needle was occurred via perineal route. Urethral localization and position

of the needle is promote this idea.

Optimal treatment depends on patient type, degree of urethral deformation, and shape of the foreign body. Main treatment is complete removal of foreign body with minimal complications. Removal of foreign body is determined by its physical attributes with the aim to minimize urothelial trauma. Various methods of foreign body removal have been described such as meatotomy, cystoscopy, internal and external urethrotomy, and suprapubic cystotomy. Foreign bodies located distal to the urogenital diaphragm can often be successfully extracted by endoscopic methods and endoscopic removal of foreign bodies is often considered the first treatment choice but sometimes requiring open surgery.<sup>2,4,10</sup> We performed open surgery and incision of corpus spongiosum without urethrotomy because of the dangerous localization of the needle. The needle was seen in corpus spongiosum, therefore urethrotomy not required.

In our case, the urethral foreign body was confirmed with retrograde urethrography because of non-self inserted nature. So, the needle could placed in perineum outside of the urethra. The needle might placed into the urethra accidentally straddle to the needle via the perineal route.

The tapestry needle was trapped in the urethral mucosa in front of the external urethral sphincter on endoscopic visualization in our patient; hence endoscopic removal of needle may cause damage of the urethra and sphincter. So, we successfully removed the needle with open surgery.

## Conclusions

Main treatment for the removal of foreign bodies from the urethra is usually endoscopic but open surgery may be required in some

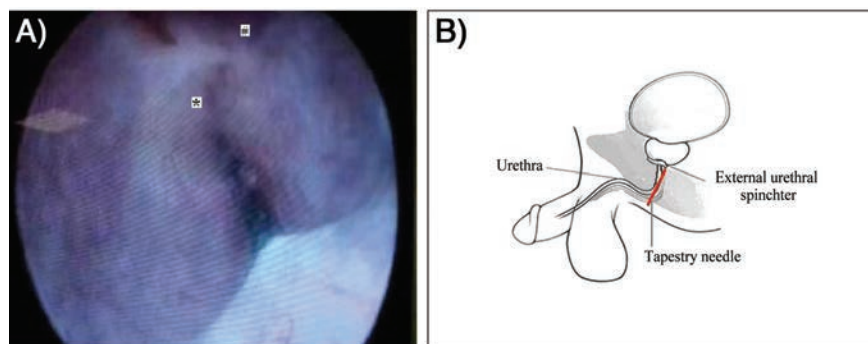


Figure 2. A) The needle was trapped in bulbous urethral mucosa in endoscopic visualization. \*Featheredge of the needle. #External urethral sphincter. B) Illustration of the needle localization: The needle was right in front of the external urethral sphincter and featheredge of it was in the sphincteric area.



Figure 3. The tapestry needle, which was successfully removed from urethra.

cases especially cutting foreign bodies such as a needle or others.

## References

1. Forde JC, Casey RG, Grainger R. An unusual penpal: case report and literature review of posterior urethral injuries secondary to foreign body insertion. *Can J Urol* 2009;16:4757-59.
2. Sukkarieh T, Smaldone M, Shah B. Multiple foreign bodies in the anterior and posterior urethra. *Int Braz J Urol* 2004;30:219-20.
3. Trehan RK, Haroon A, Memon S, Turner D. Successful removal of a telephone cable, a foreign body through the urethra into the bladder: a case report. *J Med Case Rep* 2007;27:153.
4. Naidu K, Chung A, Mulcahy M. An unusual urethral foreign body. *Int J Surg Case Rep* 2013;4:1052-54.
5. Rieder J, Brusky J, Tran V, et al. Review of intentionally self-inflicted, accidental and iatrogenic foreign objects in the genitourinary tract. *Urol Int* 2010;84:471-5.
6. Wykes WN, Barker JR. Urethral discharge associated with ingested foreign body. *BMJ* 1978;2:1751.
7. Carruthers RH. An unusual urethral foreign body. *Can Med Assoc J* 1959;80:829.
8. Seery WH, Dorfman J, Smulewicz JJ. Iatrogenic foreign body in the posterior urethra. *J Natl Med Assoc* 1976;68:63.
9. Frenkl TL, Rackley RR, Vasavada SP, Goldman HB. Management of iatrogenic foreign bodies of the bladder and urethra following pelvic floor surgery. *Neurourol Urodyn* 2008;27:491-5.
10. Ali Khan S, Kaiser CW, Dailey B, Krane R. Unusual foreign body in the urethra. *Urol Int* 1984;39:184-6.
11. Costa G, Di Tonno F, Capodiecici S, et al. Self-introduction of foreign bodies into the urethra: a multidisciplinary problem. *Int Urol Nephrol* 1993;25:77-81.

Non commercial use only