

A rare case of multiple jejunal diverticulosis presenting as intestinal obstruction

Alok Tiwari, Vijay Gupta, Priya Hazrah, Romesh Lal

Department of Surgery, Lady Hardinge Medical College, New Delhi, India

Abstract

Diverticulosis is rare in jejunum and its unusual presentation of mechanical obstruction is difficult to diagnose pre-operatively. We report a case of a 54-year old male patient who had symptoms of general abdominal pain and vomiting off and on for three years. He had been assessed elsewhere and had received a course of anti-tubercular treatment empirically based on features of recurrent intestinal obstruction due to prevalence of tuberculosis in this region. The patient had presented himself with signs and symptoms of dynamic intestinal obstruction. On examination, the abdomen was found to be swollen with a central abdominal distension and hyperactive bowel sounds. The erect abdominal radiograph showed multiple air-fluid levels and dilated jejunal loops. Following this, the patient underwent an emergency exploratory laparotomy. This revealed multiple jejunal diverticulae, multiple bands and adhesions involving jejunum and proximal ileum. The bands and adhesions were removed and the jejunum was resected along with the inflamed diverticulae.

Introduction

Jejunal diverticulosis is a rare entity accounting for 0.5-2.3% of all small bowel contrast studies, 0.3-4.5% of autopsies, and 2.3% of enteroclysis. It is usually asymptomatic and diagnosed incidentally at laparotomy. Patients present with non-specific symptoms of chronic abdominal pain, distension, nausea, vomiting, diarrhea and malabsorption. Complications include hemorrhage, perforation, diverticulitis, enterolith formation and intestinal obstruction.

Repeated diverticulitis results in formation of bands and adhesions and mechanical intestinal obstruction.

We report a case of multiple jejunal diverticulitis presenting as intestinal obstruction due to formation of multiple bands and adhesions.

Case Report

A 54-year old male patient presented himself at the Emergency Department with extensive abdominal pain and multiple episodes of bilious vomiting for the previous two days. The patient had a history of multiple episodes of pain and occasional fullness in the upper abdomen for the previous three years. The patient had earlier taken a complete course of anti-tubercular treatment empirically based on features of recurrent intestinal obstruction at other medical centers on the pretext of the prevalence of tuberculosis in this region. On presentation, the patient was found to be hemodynamically stable. Abdominal examination showed distension in the epigastric and umbilical regions with localized tenderness and hyperactive bowel sounds.

Laboratory work-up revealed raised blood urea and serum creatinine. Contrast enhanced computed tomography was, therefore, not performed but erect and supine abdominal radiographs revealed multiple air fluid levels (Figure 1A) and dilated jejunal loops (Figure 1B), respectively.

A diagnosis of acute intestinal obstruction was made after which an emergency exploratory laparotomy was performed. This revealed multiple inflamed diverticulae (Figure 2) in the jejunum with a band 15 cm from ligament of Treitz. The largest diverticulum was 5×4×4 cm at the mesentric border (Figure 3) with multiple adhesions (Figure 4) in jejunum and proximal ileum forming a blind loop. Pin-point pus exudation was seen from one of the diverticulum (Figure 5). A segmental resection of two and half feet of jejunum with end-to-end jejuno-jejunostomy was performed after removing all the bands and adhesions. The patient's post-operative course was uneventful and the patient was discharged on Day 10 after surgery. The histopathological examination of the specimen showed focal mucosal ulceration with sub-mucosal edema and chronic inflammatory infiltrate, whereas multiple sections taken from diverticulae exhibited features of diverticulitis along with an area of stricture.

Discussion

Jejunal diverticulum is an acquired condition first described in 1974 by Sommerings and later by Astley Cooler. It is a false diverticulum (in contrast to Meckel's diverticulum) characterized by herniation of only mucosa and sub-mucosa, and lacks a muscularis propria.^{1,2} The incidence of small bowel diverticulosis is very low compared to colonic diverticulosis that is found in 15-40% of adults over 40 years of age.³ Jejunal and ileal diverticulosis affect only 0.7-

Correspondence: Alok Tiwari, Department of Surgery, Lady Hardinge, Medical College and associated Dr RML hospital, New Delhi, India. Tel. +91.09716479629. E-mail: dralokty1@gmail.com

Key words: jejunal diverticulosis, small bowel obstruction, bands, localized cocoon.

Consent: written informed consent was obtained from the patient for publication of this case report and any accompanying images.

Conflict of interests: the authors declare no potential conflict of interests.

Contributions: the authors contributed equally.

Received for publication: 24 March 2013.

Revision received: 7 June 2013.

Accepted for publication: 11 June 2013.

This work is licensed under a Creative Commons Attribution NonCommercial 3.0 License (CC BY-NC 3.0).

©Copyright A. Tiwari et al., 2013
Licensee PAGEPress, Italy
Clinics and Practice 2013; 3:e21
doi:10.4081/cp.2013.e21

1% of the population. Jejunal diverticulum is usually asymptomatic until it is associated with complications. The patient presents with chronic abdominal discomfort, dyspepsia with vague abdominal pain, nausea and vomiting. Complications occur in 15% of cases and include inflammation, obstruction (dynamic/adynamic), perforation and hemorrhage. Adynamic intestinal obstruction is most common with jejunal diverticulosis occurring as a result of peritonitis, perforations, strangulation or incarceration of enterolith. Whereas dynamic intestinal obstruction occurs only in 2.3-4.6% of cases and may arise as enterolith formation, intussusception and volvulus, adhesive band formation occurs as a result of previous diverticulitis.⁴⁻⁷

There are very few cases reported in literature of jejunal diverticulosis presenting as a case of intestinal obstruction due to adhesions and band formations. In 2009, Nejmeddine *et al.* reported a case of jejunal diverticulum with acute intestinal obstruction caused as a result of band formation.⁸ In 2005, Lin *et al.* reported strangulation due to mesodiverticular band formation.⁹ In 1999, Lobo *et al.* reported dynamic intestinal obstruction as the most frequent complication of jejunal diverticulum.¹⁰ In 2008, Balducci *et al.* reported a case of jejunal diverticulum causing intestinal obstruction.¹¹ Diagnostic evaluation includes plain abdominal X-ray that can reveal multiple air-fluid levels and distension of jejunum. *Barium meal follow through* reveals diverticulum as a con-

trast filled-out pouching but the best diagnostic imaging methods are enteroclysis and enteroscopy.

Treatment

No treatment is required for asymptomatic

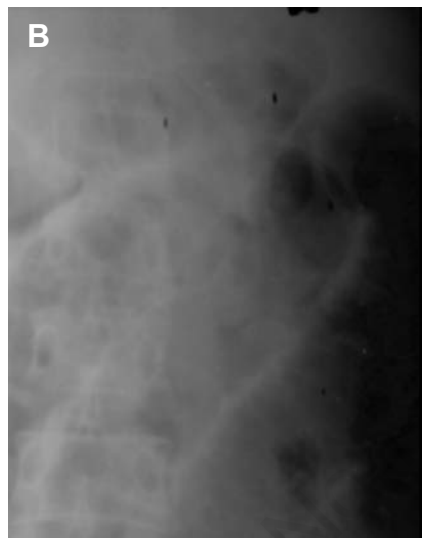
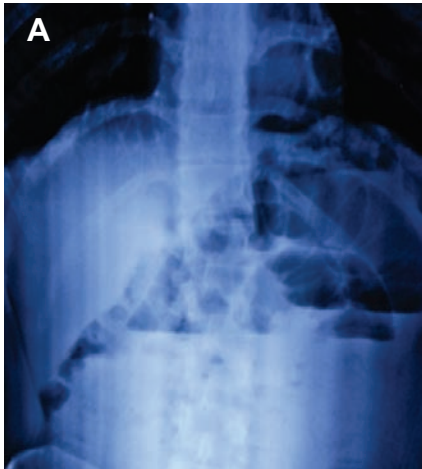


Figure 1. (A) Erect abdominal radiograph revealing multiple air-fluid levels; (B) Supine abdominal radiograph showing dilated jejunal loops.

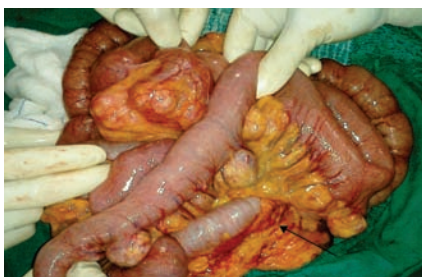

Figure 2. Emergency exploratory laparotomy revealing multiple inflamed jejunal diverticulum with band (thin arrow).

jejunal diverticulum. The recommended treatment for jejunal diverticulum is resection, often performed as emergency surgery, and end-to-end anastomosis to avoid further complications. For symptomatic diverticulum or bleeding diverticulum, the treatment is simple diverticulectomy by wedge excision and then clearing the bowel longitudinally or transversely. For enterolith, its removal by enterotomy is made in less edematous segment or an approach of corrective management is adopted entailing manual breakage of all stones and pushing the fragments to the colon.

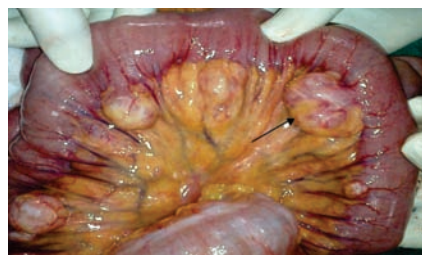

Figure 3. Largest inflamed diverticulum (5×4×4 cm) at mesenteric border (thin arrow).

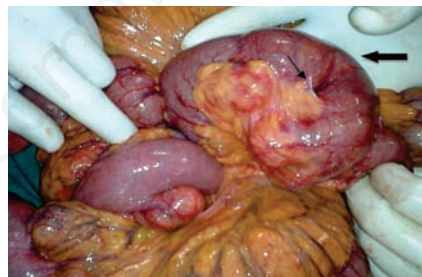

Figure 4. Diverticulum with multiple adhesions (thin arrow) forming a localized cocoon (thick arrow).

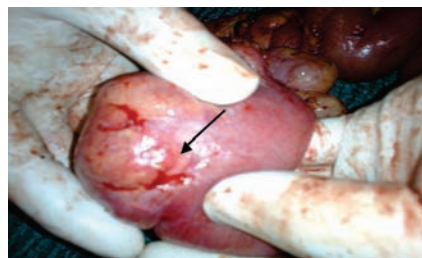


Figure 5. Pin-point pus exudation from one of the diverticulae.

Conclusions

Jejunal diverticulosis is often clinically silent with equivocal symptoms in uncomplicated cases resulting in diagnostic delay. Therefore, its treatment should be based on integrated pre-diagnostic approaches such as physical abdominal examination, abdominal radiograph and *barium meal follow through* to assess the patient for possible complications. Diagnosis is also best supported by enteroclysis and enteroscopy to confirm jejunal diverticulitis. As soon as this is confirmed, a decision to proceed to immediate laparotomy needs to be made for diverticular resection and surgical removal of bands and adhesions to prevent further complications that could lead to internal hemorrhage, perforation, intestinal obstruction, strangulation, enterolith formation and pus exudation. This relieves the patient and ensures an uneventful post-operative discharge.

References

1. Rains AJH, Mann CV, eds. Bailey and Love's short practice of surgery. 20th ed. London: HK Lewis; 1988.
2. Alam S, Bobby DVM, Balu K. Intestinal Obstruction due to multiple jejunal diverticulae. *Indian J Surg* 2005;67:224.
3. Lacz NL, Zurlo JV. Small bowel diverticulitis: an often overlooked cause of acute abdomen. *Emerg Radiol* 2010;17:497-501.
4. Bree ED, Grammatikakis J, Christodoulakis M, Tsiftsis D. The clinical significance of acquired jejunoileal diverticula. *Am J Gastroenterol* 1998;93:2523-8.
5. Fronticelli CM, Bellora P, Ferrero A, et al. Complicated jejunal diverticulosis: report of a case. *Surg Today* 1996;26:192-5.
6. Chiu KW, Changchien CS, Chuah SK. Small-bowel diverticulum: is it a risk for small-bowel volvulus? *J Clin Gastroenterol* 1994;19:176-7.
7. Palder SB, Frey CB. Jejunal diverticulosis. *Arch Surg* 1988;123:889-94.
8. Nejmeddine A, Bassema A, Mohamed H, et al. Complicated jejunal diverticulosis: a case report with literature review. *North Am J Med Sci* 2009;1:196-9.
9. Lin CH, Hsieh HF, Yu CY, et al. Diverticulosis of the jejunum with intestinal obstruction: a case report. *World J Gastroenterol* 2005;11:5416-7.
10. Lobo DN, Braithwaite BD, Fairbrother BJ. Enterolith ileus complicating jejunal diverticulosis. *J Clin Gastroenterol* 1999;29:192-3.
11. Balducci G, Dente M, Cosenza G, et al. Multiple giant diverticula of the foregut causing upper gastrointestinal obstruction. *World J Gastroenterol* 2008;14:3259-61.